

LARGE ROTATOR CUFF REPAIR PROTOCOL

The intent of this protocol is to provide the clinician with instruction, direction, rehabilitative guidelines and functional goals for all rotator cuff repair procedures. It is not intended to be a substitute for clinical decision-making regarding the progression of a patient's post-operative course based on physical exam/findings and individual progress. The physiotherapist must exercise their best professional judgment to determine how to integrate this protocol into an appropriate treatment plan. The general treatment for a variety of shoulder procedures involves protection of the repair, stretching/mobilizing tight or restricted structures, strengthening the rotator cuff and strengthening and retraining the scapular musculature.

This particular protocol divided into 4 phases and the timeline can vary from 4 months to 1 year: Phase 1: Passive range of motion; Phase II: Active assisted→active range of motion; Phase III: Resisted exercises/strengthening; Phase IV: Advanced strengthening/dynamic stability. Therefore, decisions to advance patients through the phases of rehabilitation should be based on achieving the appropriate level of soft tissue healing, as well as clinical presentation and response to treatment. As an individual's progress is variable and each will possess various pre-operative deficiencies, this protocol must be individualized for optimal return to activity. Some exercises may be adapted depending on the equipment availability at each facility. There may be slight variations in this protocol or additional restrictions placed by the surgeon post-operatively depending on findings at the time of the surgery. If a clinician requires assistance in treatment progression please contact the referring physician or the physiotherapy department.

GENERAL CLASSIFICATION OF ROTATOR CUFF TEAR SIZE¹

Small: <1cm in length **Medium:** 1-3 cm **Large:** 3-5 cm **Massive:** >5 cm

Also, tears are described as either **partial** or **full** thickness depending on the amount of tissue damage. Partial tears do not go all the way through the cuff, although a large surface area may be involved either on the bursal side or, more commonly, on the articular side of the tendon(s). Full tears are completely through the tendon(s) (similar to a button-hole on a shirt) creating a gap/hole in the cuff.

GENERAL CONSIDERATIONS FOR ROTATOR CUFF REPAIR

1. Quality of tissue and integrity of repair² (stronger tissue if <50 years old). This includes the quality of the tendon, muscular tissue, and bone. Rehabilitation for the patient with good or adequate tissue would be a slightly more aggressive program, whereas the patient with poor tissue quality would follow a more conservative approach.
2. Acute vs. chronic tears/duration. Longer duration of symptoms has been correlated with histological changes in the muscle that are often progressive and irreversible and potentially increase the difficulty of repair.³ As a result, active ROM can be more difficult to achieve with chronic tears.
3. Trauma vs. degenerative tear (traumatic tears tend to have better outcomes)⁴
4. Tear size (large/massive tear or >1 tendon repair difficult to achieve full ROM, caution with AROM and resisted exercises with chronic/large tears). Functional outcome is directly related to size of the tear⁴. Therefore, the rate of progression for post-surgical rehabilitation should vary based on the size and extent of the tear. The rate of progression following rotator cuff repair surgery is often determined by the amount of retraction present prior to repair, with the more retracted tendon requiring a slower rehabilitation course because of a higher postoperative failure rate.
5. First vs. revision surgery (revisions can be more prone to fibrosis and pain)²
6. Use pain as in indicator of progression. Pain should decrease over time.
7. The early focus of physiotherapy is on achieving ROM before emphasizing strengthening. Early PROM of GH joint is essential to prevent capsular adhesions and fibrosis. This is done with muscles in a shortened position. (Supraspinatus repair: avoid passive IR, Hor Add, Ext. SubScapularis repair: avoid passive ER, Hor Add, Ext). It

has been shown the greatest improvement in strength recovery are during the first 6 months after surgery but to reach near-maximum strength recovery it can take up to 1 year.^{5,6} Recovery of strength is correlated to tear size: a) small and medium tears strength recovery = almost complete during the first year, b) large and massive tears = much slower and less consistent.⁵

STRESS/STRAIN AND ROM ON HEALING ROTATOR CUFF TISSUE

Tendon-to-bone healing is slow after injury/surgery as tendons have lower oxygen uptake than skeletal muscle⁷. It has been shown in animal studies that healing begins with the formation of a fibro-vascular tissue interface between tendon and bone.^{8,9} The bone grows into the interface tissue¹⁰ and gradually, collagen fibre continuity is created between the tendon and bone¹¹. It requires at least 12 weeks of healing to allow adequate pull-out strength of the repair.¹² As a result, strengthening should be postponed until this general timeline.

Following rotator cuff repair surgery, a post-operative abduction pillow brace supporting the shoulder >30° abduction is used, for a minimum of 2-6 weeks, as there is documented evidence that there is less strain on the repaired supraspinatus tendon in that range vs. arm at side.¹³ Furthermore, strain is lowest in the scapular and coronal plane vs. the sagittal plane.¹³ Generally, passive external rotation is restricted to 60° with the arm at >30° elevation in the scapular or coronal plane to avoid excessive tension on the repair. Since active and passive ROM exercises can significantly increase strain on the repair site, they should be used with caution in certain ranges on a healing rotator cuff.

Large tears that extend into the posterior cuff (infraspinatus and teres minor) require greater protection and excessive internal rotation should be restricted. With these tears, external rotation strengthening should be progressed at a slower rate. Initiating rotator cuff and scapula stabilization strengthening exercises should be approached with caution to prevent stress applied to the healing tissues. Stress applied too early or too aggressively could lead to gap formation, pain, and re-tearing of the repair. When appropriate, sub maximal and pain-free multiangle isometrics for ER and IR should be performed to prevent muscular atrophy and to minimize rotator cuff inhibition.

ROLE OF THE ROTATOR CUFF

The main role of the rotator cuff is to centralize and compress the humeral head in the glenoid fossa to maintain the instantaneous centre of rotation of the glenohumeral joint during arm movement. To be effective there must be an equal anterior/posterior balance rotator cuff (subscapularis = infraspinatus+teres minor) as well as an equal superior/inferior balance between the entire cuff and the deltoid muscles (subscapularis+infraspinatus+teres minor = deltoid). If one part of the cuff is torn/deficient an imbalance will result and the translatory force of the deltoid will pull the humerus in a superior direction up under the acromion leading to mechanical impingement. Exercises that produce the most supraspinatus and least deltoid activity may avoid potential deleterious superior humeral head migration associated with high deltoid activity. Restoration of these force couples is vital at the appropriate time in rotator cuff rehabilitation.

SCAPULAR MOVEMENT

The scapula moves around three axes and has six movements: up/downward rotation, internal/external rotation, anterior/posterior tipping through muscle control. (protraction/retraction refers to movement around the thorax). With the arm at side, the glenoid fossa is tilted 5° into upward rotation. At 90° of abduction the glenoid fossa is tilted enough to provide a stable platform to prevent inferior translation. In full abduction, the glenoid fossa is in upward rotation, external rotation and posterior tilt.^{14,15} Subjects with shoulder pain have been shown to lack upward rotation and posterior tilt^{16,17} resulting in less clearance space for the rotator cuff during elevation. Restoration of upward rotation and posterior tilt is important to establish in rotator cuff rehabilitation to establish proper overhead mechanics.

SCAPULAR FORCE COUPLES

There is a moving axis of rotation that commences at the root of the spine of the scapula on initiation of movement and travels along the spine of the scapula to the AC joint at the end range of elevation and abduction.

The main muscles that control scapular movement are trapezius, serratus anterior, rhomboids, levator scapula and pectoralis minor (see chart below). The most influential force couple that acts to upwardly rotate the scapula (glenoid fossa) is the trapezius (upper and lower fibres) and serratus anterior. From a pathology standpoint, this force couple is often the problem source and can become dyskinetic during either/both concentric or eccentric phases of movement.¹⁸

Muscle	Action
Upper Trapezius	Upward rotation, retraction, elevation
Middle Trapezius	Upward rotation, retraction
Lower Trapezius	Upward rotation, retraction, depression
Serratus Anterior	Upward rotation, protraction
Rhomboids	Downward rotation, retraction, elevation
Levator Scapulae	Downward rotation, elevation
Pectoralis Minor	Anterior tipping

QUALITY VS. COMPENSATION

Physiotherapists often feel compelled to progress patients by giving them new exercises each time they are in for therapy. It cannot be stressed enough that it is **not** beneficial to give patients exercises they are not neuromuscularly ready for. It is very important to observe the *quality* of the exercises that are being performed, specifically with rotator cuff and scapular stabilization exercises. Weaknesses in specific muscle groups lead to compensations, which produce faulty movement patterns. These faulty patterns are then integrated into unconscious motor programs, which perpetuate the original weakness.¹⁹

Phase 1: Passive Range of Motion 0 to 8-10 weeks

GOALS

- Patient Education: posture, joint protection, positioning, hygiene...
- Sling +/- abduction pillow for a minimum of 2-6 weeks post-surgery for comfort and to protect the integrity of the rotator cuff repair.¹³ Remove for showering and range of motion exercises
- Minimize postoperative pain and inflammation
- Controlled passive shoulder motion (under therapist supervision and within pain limits)
- Prevent post-operative stiffness²⁰
- Normalize scapular position and mobility

PRECAUTIONS

- This stage is characterized biologically by a slight coagulation of fibrin with type III/weak collagen²⁰ and the repair can only withstand minimal loads.
- Avoid active shoulder flexion/abduction or active muscle contraction in the first 6 weeks i.e. lifting, carrying, pushing, pulling, driving

EXERCISE SUGGESTIONS:

Muscle Activation

General:

- Posture awareness /exercises
- Ball/theraputty squeezes¹⁹ (avoid if biceps repair or tenodesis done)²¹
- Pendulums forward/back, side/side for pain control and joint stiffness

Note: For passive pendulums, the arm should dangle and the muscles must be completely relaxed. Move the arm by rocking the body forward/back, side to side or in circles **NOT** by moving the arm.²²

Scapula: *with sling on

- Elevation/depression, retraction/protraction²³
- Scapular orientation: ensure patient can achieve proper scapular positioning (typically emphasize posterior tilt with some elevation /upward rotation, external rotation/retraction)

ROM

Muscle activity levels during range of motion exercise have been measured using EMG²⁴. Therapist assisted passive joint mobility exercises with the patient in supine minimized muscular activity. Conversely, shoulder musculature was most active with the rope-and-pulley ROM exercise.

As a result, passive ROM exercises should be given first (in Phase I) and progressed to active-assisted ROM exercise (i.e. pulleys) once adequate tissue healing occurs (Phase II). Specifically, passive ROM into flexion >30° and ROM in the scapular plane has been shown to reduce stress on the repair site.¹³

- **Elbow & Wrist:** Active & passive - flexion/extension/pronation/supination¹⁹ (avoid elbow flexion if biceps repair or tenodesis)²¹
- **Neck:** general ROM if needed
- **Shoulder:** PASSIVE motion in a supine position through a comfortable range
 - 0-2 weeks: **NO** range of motion except home exercises given by hospital PT
 - 2-6 weeks: therapist guided supine range of motion in therapy sessions/assistant at home
 - 6-8 weeks: patient passive ROM with cane/stick
 - Passive abduction & scaption: slowly progress ROM to active-assisted ROM painfree
 - Bent-arm self-assisted scaption and forward flexion to 90°+¹⁹
 - Passive ER/IR at 30° abduction/scapular plane: 0-60° (unless subscapularis repaired)

Modalities

- Ice 15 minutes every few hours²³
- Interferential current therapy (pain relief)

MILESTONES TO PROGRESS TO PHASE II

1. Pain control
2. Acceptable glenohumeral joint range of motion in flexion, scaption/abduction, and external rotation

Phase II: Active Assisted→Active Range of Motion 8-10 to 14-18 weeks (4½ months)

GOALS

- Ensure adequate mobility specific to glenohumeral joint (~90-120° GH flexion & abduction)
- Active-assisted ROM with progression to active ROM exercises to progressively restore motion without scapular compensation
- Resting pain should be considerably decreased
- Establish baseline humeral head control
- Initiation of functional activities/ADLs and proprioception exercises below shoulder height

PRECAUTIONS

- Do not load, lift, push or pull with affected arm
- No rapid movements/gestures (excessive muscle contraction)

EXERCISE SUGGESTIONS:

PROM & AAROM

- Use cane/stick (PROM) progressions: supine → 45° semi-reclined → sitting/standing → pulleys (=AAROM):
 - Scaption & abduction and flexion above shoulder level (as tolerated)
 - Continue with ER range in abduction/scapular plane >30° elevation (as tolerated)
- Hydrotherapy/Pool²⁵⁻²⁷ = AAROM (ensure good glenohumeral movement to avoid scapular hitching)

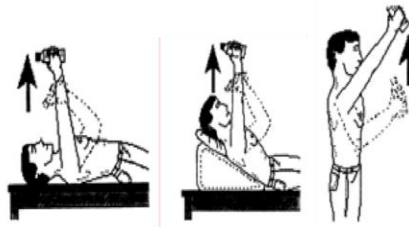
AROM

- Supine cane/stick progress to wall/towel slides¹⁹ and then to no assistance (AROM)
 - Scaption/abduction & flexion 0-140° (or as tolerated)

Note: Flexion in supine position from 0-90° is against gravity but, flexion above 90° then becomes gravity assisted. This exercise can be carried out at the beginning with the elbow flexed and then gradually increasing the lever arm by extending the elbow.

Progression of Flexion:

By the end of this stage (see timeline above depending on tear size), patients should be able to actively raise the arm against gravity in standing. If unable, continue with flexion in supine, then progress to a 45° semi-reclined ('lawn chair') position and then finally to standing. If the patient has poor technique when progressing from supine to 45° semi-reclined, an alternative exercise is side-lying shoulder flexion. If this substitution is necessary, the 45° semi-reclined progressions should be reinstated once the patient is proficient with the side-lying flexion exercise.



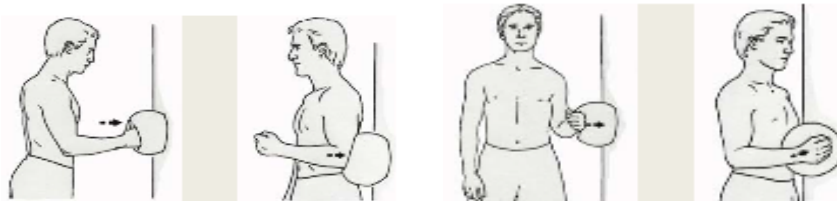
Muscle Strength & Endurance

General:

- Continue with pendulums for pain relief if required
- Posture awareness / exercises

Rotator Cuff: (initiate isometrics/isotonics when 80% AROM achieved)⁵

The goal of initiating isometrics is to “wake up” and activate the cuff NOT strengthen. The amount of force is extremely low and should be equivalent to pressing into a balloon.



- **Sub-Maximal Isometrics:**
 - ER/IR and adduction with arm supported in 30° abduction²⁸
 - *caution with IR if subscapularis is repaired²³
 - Shoulder flexion & extension (push/pull with elbow at 90°)
 - Elbow flexion (avoid if biceps tenodesis/tenotomy), extension
- Light Isotonics = AROM against gravity
 - Sidelying ER with pillow/towel (~30° abduction) no weight +/- muscle stimulation²⁹

Scapula:

- Continue with protraction, retraction, elevation, depression
- Manual resistance for scapular motions
- Posterior tilt of scapula
- Closed chain scapulothoracic stability & proprioception at ranges below 60° of elevation²³
i.e. large theraball on floor: circles clockwise and counterclockwise +/- pushing into ball
- Prone arms raises at 0°
- Swiss ball slides up wall in flexion and scaption¹⁹

Mobilizations

- GH mobilizations (Grade II-III) to attain adequate GH mobility and pain control
- Scar massage if incisions completely healed

Cardiovascular (as tolerated)

- Stationary bicycle, treadmill, stairmaster, elliptical trainer (no arms), walking¹⁹

MILESTONES TO PROGRESS TO PHASE III

1. Good resting scapular posture and dynamic scapular control with ROM and strengthening exercises.
2. Satisfactory active range of movement without pain or compensation i.e. Flexion: 30 repetitions in standing without upper trapezius substitution, External rotation: 30 repetitions in side-lying without weight

Phase III: Resisted Exercises/Strengthening 14-18 to 24 weeks (6 months)

GOALS

- Satisfactory range of movement, especially flexion and external rotation
- Progress AROM as tolerated – should be nearly full
- Flexion 160° +

- ER at side, at 45° and 90° abduction
- Restore dynamic humeral head control
- Increase external rotation strength/endurance
- Address specific deficits of the affected upper extremity
- Progression of functional activities/heavier ADLs below shoulder height
- Non-painful normal range of motion

PRECAUTIONS

- Avoid overhead loads with affected arm
- Avoid activities which cause pain
- Avoid Full and Empty can exercises – the long lever places too much stress on the rotator cuff

EXERCISE SUGGESTIONS:

AROM

- Overhead wall slide/walking: forward, scaption
- Ball slides/roll up wall (90°-160°+ flexion/scaption/abduction)

Muscle Strength & Endurance

Note: Progression is endurance then strength. Exercises should have high repetitions (4x15 or 3x30) before adding resistance. Closely monitor shoulder/postural mechanics and pain throughout all exercises.

Rotator Cuff:

- Light Isotonics
 - Sidelying ER with towel (30° abduction) +/-muscle stimulation progress to 1lb
 - Light resistance tubing¹⁹ (red) ER/IR (30° abduction) with towel
 - Progress 45°→90° as tolerated +/- support and then arm at side (0°)(strain values highest)
- Low force rhythmic stabilization spine 90° flexion and ER/IR@45° abduction (for humeral head control)

Scapula:

- Supine/standing protraction/retraction + weights/tubing
- Prone/seated rowing¹⁹ progress to pulleys, tubing etc.
- Forward punches with pulleys, tubing...
- Dynamic hug → with tubing¹⁹
- Light resistance shoulder extension, adduction, flexion¹⁹ (good patterning required!!)
- PNF patterning – none to light resistance only
- Closed chain proprioception progression at and above shoulder height. i.e.Weight-bearing protraction/retraction: supine at 90, wall, plinth, hands & knees....
- Ball stabilization on wall
- Wall washes¹⁹
- Push-up with plus¹⁹ progress from on wall →plinth → floor

Mobilizations and Stretching

- GH mobilizations (Grade III – IV) for mobility
- Gentle stretches if needed for¹⁹: anterior or posterior shoulder, internal rotation

Cardiovascular (as tolerated)

- Continue with stationary bicycle, treadmill, stairmaster, elliptical trainer (no arms), walking¹⁹

MILESTONES TO PROGRESS TO PHASE IV

1. If ROM limited: emphasize Full ROM; if ROM is full and pain-free, emphasis is on strengthening.....
2. Moderate strength in the affected arm. Note: Increase the number of repetitions before adding resistance i.e. 50-60 repetitions before increasing by 1pound/½ kilo without compromising shoulder/postural mechanics or pain throughout exercises.
3. Satisfactory endurance if cleared to perform i.e. 1 minute intervals with: a) external rotation at 30-45° abduction, b) external rotation at 90° abduction and c) internal rotation at 90° abduction d) rhythmic stabilization without increased pain after treatment

Phase IV: Advanced Strengthening & Dynamic Stability (6 months+ up to 1 year)

This end point will differ depending on the patient. At this phase/stage a shoulder with a low functional demand may continue to improve in a progressive manner with a home program.

GOALS

- Full pain free AROM
- Continue to improve muscular strength, stability and endurance with emphasis on external rotation strength
- Functional activities/ADLs above shoulder height (progress with weight +/- repetition)
- Advance strengthening program +/- plyometric training ** only if required
- Return to desired activities i.e. heavier labour, overhead sports...²⁵

PRECAUTIONS

- It is not acceptable to experience pain with activities/exercise. This indicates the load/stresses place on the arm are too much!!

EXERCISE SUGGESTIONS:

Muscle Strength & Endurance

General:

- Biceps/Triceps
- Chest press
- Shoulder press (military press)
- Flys / Reverse flys
- Lat Pull downs
- Full push up

Rotator Cuff:

- ER/IR at side, 45°, 90° – vary speed, resistance & position (sidelying, standing, prone)
- Hands and knees closed chain perturbations¹⁹ progress to hands and feet

Scapula:

- Continue with shoulder strengthening program as initiated in Phase III with emphasis on faster speed, multiplanar activities which incorporate the kinetic chain
- PNF diagonal patterns with bands/pulleys/manual resistance¹⁹:
- D1 extension (high back hand to down to hitch hike position)
- D1 flexion (hitch hike to high back hand position)
- D2 extension (carry tray to hand in opposite front pocket position)

- D2 flexion (hand in opposite front pocket to carry tray position)

Plyometric Program (if needed)

Plyometric exercises are advanced from 2-arm, short-lever-arm activities below 90° of arm elevation, to single-arm long-lever-arm activities above 90° of arm elevation and should be specific to mimic a functional task/activity.²¹

Suggestions/ideas:

- Tubing plyometrics for ER/IR at 90° abduction with varying speeds
- 2 handed tosses: waist/chest level → overhead → diagonal (PNF pattern)
- 1 handed tosses: begin throw with shoulder flexion and mostly elbow extension → progress by increasing the amount of shoulder abduction/ER
- Begin with towel, beach ball, kid's ball, tennis ball → progression to lightly weighted balls (plyoballs)

Cardiovascular Fitness

- Train specific to demand of sport (aerobic, anaerobic)

MILESTONES TO RETURN TO SPORT, WORK, HOBBIES

1. Therapist/Physician clearance
2. No complaints of pain at rest, with exercises or activities
3. Sufficient ROM to meet task demands
4. Good/Full strength and endurance of rotator cuff and scapular muscles for desired activities

Large Rotator Cuff Repair: Guidelines for Manual Therapy and Exercise

	Phase I	Phase II	Phase III	Phase IV
Range of Motion:				
Neck, elbow, wrist exercises	●			
Therapist guided supine passive ROM	●			
Pendulums (body sway forward/back, side/side)	●	●		
Cane/Stick/Self assist (passive only start 6-8 weeks)		●		
Pulleys		●	●	
Forearm towel slides up wall		●	●	
Finger ladder (bent elbow → straight elbow)		●	●	
GH mobilizations (only if needed in the limited direction)		●	●	
Stretches if needed			●	
Muscle Strength & Endurance				
General:				
Ball squeezes	●			
Posture Awareness / Exercises	●	●		
Rotator Cuff:				
Sub max isometrics		●		
Isotonics: side lying ER no weight (+/- muscle stimulation) → increase weight slowly		●	●	
ER progressions: weight, resistance, position, speed...			●	●
ER/IR: at side, 45°, 90° (wts, pulleys, resistance tubing)			●	●
Rhythmic stabilization for rotator cuff strengthening (ER/IR at 45° abduction in scapular plane) – low force → increase resistance/speed			●	●

	Phase I	Phase II	Phase III	Phase IV
Scapula:				
Bilateral scapular retraction, shoulder rotations...	●	●		
Ball slides/roll up wall: flexion, scaption		●		
Closed chain scapulothoracic stability < 60° elevation: ball on floor circles, pushing into ball → progress at and above shoulder height i.e. WB protraction/retraction: supine at 90, wall, plinth, hands & knees....		●	●	
Prone arm raises at 0° progress to 90° and 120°		●	●	
Supine/standing protraction/retraction + weights/tubing			●	
Dynamic hug → with tubing			●	
Ball stabilization on wall			●	
Wall washes			●	
Prone/seated rows + pulleys, tubing, weights etc.			●	●
Forward punches with pulleys, tubing...			●	●
Extension, adduction, forward flexion, PNF patterning – light to increased resistance			●	●
Push-up with plus progress from wall → plinth → floor			●	●
Hands and knees closed chain perturbations→ hands and feet				●
PNF patterns x 4 – bands, pulleys, manual resistance				●
General Strength (Gym Program)				
Biceps/Triceps				●
Chest press / incline				●
Shoulder press (Military press)				●
Shrugs				●
Flys/Reverse Flys				●
Lat pull downs				●
Full push up				●
Plyometrics (if needed): Tubing ER/IR at 90° abduction with varying speeds; 2 handed tosses: waist/chest level→ overhead → diagonal; 1 handed toss→ progress by increasing the amount of shoulder abduction/ER				●

References

1. DeOrio JK, Cofield RH. Results of a second attempt at surgical repair of a failed initial rotator-cuff repair. J Bone Joint Surg Am 1984; 66:563-7.
2. Djurasovic M, Marra G, Arroyo JS, Pollock RG, Flatow EL, Bigliani LU. Revision rotator cuff repair: factors influencing results. J Bone Joint Surg Am 2001; 83-A:1849-55.
3. Gerber C, Fuchs B, Hodler J. The results of repair of massive tears of the rotator cuff. J Bone Joint Surg Am 2000; 82:505-15.
4. Lahteenmaki HE, Hiltunen A, Virolainen P, Nelimarkka O. Repair of full-thickness rotator cuff tears is recommended regardless of tear size and age: a retrospective study of 218 patients. J Shoulder Elbow Surg 2007; 16:586-90.
5. Rokito AS, Zuckerman JD, Gallagher MA, Cuomo F. Strength after surgical repair of the rotator cuff. J Shoulder Elbow Surg 1996; 5:12-7.
6. Bigoni M, Gorla M, Guerrasio S, Brignoli A, Cossio A, Grillo P, Marinoni EC. Shoulder evaluation with isokinetic strength testing after arthroscopic rotator cuff repairs. J Shoulder Elbow Surg 2009; 18:178-83.
7. Sharma P, Maffulli N. Biology of tendon injury: healing, modeling and remodeling. J Musculoskelet Neuronal Interact 2006; 6:181-90.

8. Rodeo SA, Arnoczky SP, Torzilli PA, Hidaka C, Warren RF. Tendon-healing in a bone tunnel. A biomechanical and histological study in the dog. *J Bone Joint Surg Am* 1993; 75:1795-803.
9. St Pierre P, Olson EJ, Elliott JJ, O'Hair KC, McKinney LA, Ryan J. Tendon-healing to cortical bone compared with healing to a cancellous trough. A biomechanical and histological evaluation in goats. *J Bone Joint Surg Am* 1995; 77:1858-66.
10. Aoki M, Oguma H, Fukushima S, Ishii S, Ohtani S, Murakami G. Fibrous connection to bone after immediate repair of the canine infraspinatus: the most effective bony surface for tendon attachment. *J Shoulder Elbow Surg* 2001; 10:123-8.
11. Oguma H, Murakami G, Takahashi-Iwanaga H, Aoki M, Ishii S. Early anchoring collagen fibers at the bone-tendon interface are conducted by woven bone formation: light microscope and scanning electron microscope observation using a canine model. *J Orthop Res* 2001; 19:873-80.
12. Ghodadra NS, Provencher MT, Verma NN, Wilk KE, Romeo AA. Open, mini-open, and all-arthroscopic rotator cuff repair surgery: indications and implications for rehabilitation. *J Orthop Sports Phys Ther* 2009; 39:81-9.
13. Hatakeyama Y, Itoi E, Pradhan RL, Urayama M, Sato K. Effect of arm elevation and rotation on the strain in the repaired rotator cuff tendon. A cadaveric study. *Am J Sports Med* 2001; 29:788-94.
14. Burkhart SS, Morgan CD, Kibler WB. The disabled throwing shoulder: spectrum of pathology Part I: pathoanatomy and biomechanics. *Arthroscopy* 2003; 19:404-20.
15. Ludewig PM, Hoff MS, Osowski EE, Meschke SA, Rundquist PJ. Relative balance of serratus anterior and upper trapezius muscle activity during push-up exercises. *Am J Sports Med* 2004; 32:484-93.
16. Endo K, Ikata T, Katoh S, Takeda Y. Radiographic assessment of scapular rotational tilt in chronic shoulder impingement syndrome. *J Orthop Sci* 2001; 6:3-10.
17. Lukasiewicz AC, McClure P, Michener L, Pratt N, Sennett B. Comparison of 3-dimensional scapular position and orientation between subjects with and without shoulder impingement. *J Orthop Sports Phys Ther* 1999; 29:574,83; discussion 584-6.
18. Bourne DA, Choo AM, Regan WD, MacIntyre DL, Oxland TR. Three-dimensional rotation of the scapula during functional movements: an in vivo study in healthy volunteers. *J Shoulder Elbow Surg* 2007; 16:150-62.
19. Rubin BD, Kibler WB. Fundamental principles of shoulder rehabilitation: conservative to postoperative management. *Arthroscopy* 2002; 18:29-39.
20. Conti M, Garofalo R, Delle Rose G, Massazza G, Vinci E, Randelli M, Castagna A. Post-operative rehabilitation after surgical repair of the rotator cuff. *Chir Organi Mov* 2009; 93 Suppl 1:S55-63.
21. Krupp RJ, Kevern MA, Gaines MD, Kotara S, Singleton SB. Long head of the biceps tendon pain: differential diagnosis and treatment. *J Orthop Sports Phys Ther* 2009; 39:55-70.
22. Long JL, Ruberte Thiele RA, Skendzel JG, Jeon J, Hughes RE, Miller BS, Carpenter JE. Activation of the shoulder musculature during pendulum exercises and light activities. *J Orthop Sports Phys Ther* 2010; 40:230-7.
23. Hayes K, Callanan M, Walton J, Paxinos A, Murrell GA. Shoulder instability: management and rehabilitation. *J Orthop Sports Phys Ther* 2002; 32:497-509.
24. Dockery ML, Wright TW, LaStayo PC. Electromyography of the shoulder: an analysis of passive modes of exercise. *Orthopedics* 1998; 21:1181-4.
25. Murray TF, Jr, Lajtai G, Mileski RM, Snyder SJ. Arthroscopic repair of medium to large full-thickness rotator cuff tears: outcome at 2- to 6-year follow-up. *J Shoulder Elbow Surg* 2002; 11:19-24.
26. Speer KP, Warren RF, Horowitz L. The efficacy of cryotherapy in the postoperative shoulder. *J Shoulder Elbow Surg* 1996; 5:62-8.
27. Kelly BT, Roskin LA, Kirkendall DT, Speer KP. Shoulder muscle activation during aquatic and dry land exercises in nonimpaired subjects. *J Orthop Sports Phys Ther* 2000; 30:204-10.
28. Graichen H, Hinterwimmer S, von Eisenhart-Rothe R, Vogl T, Englmeier KH, Eckstein F. Effect of abducting and adducting muscle activity on glenohumeral translation, scapular kinematics and subacromial space width in vivo. *J Biomech* 2005; 38:755-60.
29. Reinold MM, Macrina LC, Wilk KE, Dugas JR, Cain EL, Andrews JR. The effect of neuromuscular electrical stimulation of the infraspinatus on shoulder external rotation force production after rotator cuff repair surgery. *Am J Sports Med* 2008; 36:2317-21.